













Correction: A case series of three patients with extensive lung metastatic pheochromocytoma/paraganglioma: evaluation, treatment challenges, and outcomes

Kailah M. Charles¹ , Matthew A. Nazari¹ , Abhishek Jha¹ , Sara Talvacchio¹ , Mickey J. M. Kuo^{1,2} , Mayank Patel^{1,3} , Alexander Ling⁴, Ali S. Alzahrani^{5,6}, Tamara Prodanov¹ , Alberta Derkyi¹, Alice Chen⁷ , John Glod⁸, Jaydira Del Rivero⁹ , Karel Pacak^{1*} 

¹Section on Medical Neuroendocrinology, Eunice Kennedy Shriver National Institute of Child Health and Human Development, National Institutes of Health, Bethesda, MD 20892, USA

²Medical Genetics Branch, National Human Genome Research Institute, National Institutes of Health, Bethesda, MD 20892, USA

³Laboratory of Pathology, Center for Cancer Research, National Cancer Institute, Bethesda, MD 20892, USA

⁴Radiology and Imaging Sciences, Warren Grant Magnuson Clinical Center, National Institutes of Health, Bethesda, MD 20892, USA

⁵Department of Molecular Oncology, King Faisal Specialist Hospital and Research Centre, Riyadh 11564, Saudi Arabia

⁶Department of Medicine, King Faisal Specialist Hospital and Research Centre, Riyadh 11564, Saudi Arabia

⁷Division of Cancer Treatment and Diagnosis, National Cancer Institute, National Institutes of Health, Bethesda, MD 20892, USA

⁸Pediatric Oncology Branch, Center for Cancer Research, National Cancer Institute, Bethesda, MD 20892, USA

⁹Developmental Therapeutics Branch, National Cancer Institute, Bethesda, MD 20892, USA

***Correspondence:** Karel Pacak, Section on Medical Neuroendocrinology, Eunice Kennedy Shriver National Institute of Child Health and Human Development, National Institutes of Health, Building 10, CRC, Room 1E-3140, 10 Center Drive, Bethesda, MD 20892, USA. karelpacak@yahoo.com

Published: December 20, 2024

Cite this article: Charles KM, Nazari MA, Jha A, Talvacchio S, Kuo MJM, Patel M, et al. Correction: A case series of three patients with extensive lung metastatic pheochromocytoma/paraganglioma: evaluation, treatment challenges, and outcomes. *Explor Endocr Metab Dis.* 2024;1:244–5. <https://doi.org/10.37349/eemd.2024.00020>

Correction to “A case series of three patients with extensive lung metastatic pheochromocytoma/paraganglioma: evaluation, treatment challenges, and outcomes” by Charles KM, et al. *Explor Endocr Metab Dis.* 2024;1:218–233. DOI: [10.37349/eemd.2024.00018](https://doi.org/10.37349/eemd.2024.00018)

The original version of this article contained errors in the references and their numbering.

The last sentence of the third paragraph in the section “Introduction” contained errors in references. References 25 and 26 have been replaced. The correct version is: “Therefore, treating both pediatric (< 18 years old) and adolescent (10 to 19 years old) metastatic PPGL with extensive pulmonary metastases presents clinical challenges (such as higher intensity of symptoms) which are discussed alongside demonstrative cases and relevant literature [9, 25, 26].”

25. Pham TH, Moir C, Thompson GB, Zarroug AE, Hamner CE, Farley D, et al. Pheochromocytoma and paraganglioma in children: a review of medical and surgical management at a tertiary care center. *Pediatrics.* 2006;118:1109–17.



26. De Tersant M, Généré L, Freyçon C, Villebasse S, Abbas R, Barlier A, et al. Pheochromocytoma and Paraganglioma in Children and Adolescents: Experience of the French Society of Pediatric Oncology (SFCE). *J Endocr Soc.* 2020;4:bvaa039.











The sixth sentence of the first paragraph in the section “Discussion” contained an error in reference number. Reference number [25] has been replaced with [27]. In the fourth sentence of the fourth paragraph in the “Treatment” section, a citation to Reference [69] has been added.

In addition, the ORCID for author Tamara Prodanov has been added, and there were a number of minor grammatical errors which have been amended. These have been corrected in the PDF and HTML versions of the article.

The original uncorrected PDF can be accessed from <https://www.explorationpub.com/uploads/er101418.pdf>



A case series of three patients with extensive lung metastatic pheochromocytoma/paraganglioma: evaluation, treatment challenges, and outcomes

Kailah M. Charles¹ , Matthew A. Nazari¹ , Abhishek Jha¹ , Sara Talvacchio¹ , Mickey J. M. Kuo^{1,2} , Mayank Patel^{1,3} , Alexander Ling⁴, Ali S. Alzahrani^{5,6}, Tamara Prodanov¹ , Alberta Derkyi¹, Alice Chen⁷ , John Glod⁸, Jaydira Del Rivero⁹ , Karel Pacak^{1*} 

¹Section on Medical Neuroendocrinology, Eunice Kennedy Shriver National Institute of Child Health and Human Development, National Institutes of Health, Bethesda, MD 20892, USA

²Medical Genetics Branch, National Human Genome Research Institute, National Institutes of Health, Bethesda, MD 20892, USA

³Laboratory of Pathology, Center for Cancer Research, National Cancer Institute, Bethesda, MD 20892, USA

⁴Radiology and Imaging Sciences, Warren Grant Magnuson Clinical Center, National Institutes of Health, Bethesda, MD 20892, USA

⁵Department of Molecular Oncology, King Faisal Specialist Hospital and Research Centre, Riyadh 11564, Saudi Arabia

⁶Department of Medicine, King Faisal Specialist Hospital and Research Centre, Riyadh 11564, Saudi Arabia

⁷Division of Cancer Treatment and Diagnosis, National Cancer Institute, National Institutes of Health, Bethesda, MD 20892, USA

⁸Pediatric Oncology Branch, Center for Cancer Research, National Cancer Institute, Bethesda, MD 20892, USA

⁹Developmental Therapeutics Branch, National Cancer Institute, Bethesda, MD 20892, USA

***Correspondence:** Karel Pacak, Section on Medical Neuroendocrinology, Eunice Kennedy Shriver National Institute of Child Health and Human Development, National Institutes of Health, Building 10, CRC, Room 1E-3140, 10 Center Drive, Bethesda, MD 20892, USA. karelpacak@yahoo.com

Academic Editor: Osborne Almeida, University of Minho, Portugal

Received: July 24, 2024 **Accepted:** October 18, 2024 **Published:** November 15, 2024

Cite this article: Charles KM, Nazari MA, Jha A, Talvacchio S, Kuo MJM, Patel M, et al. A case series of three patients with extensive lung metastatic pheochromocytoma/paraganglioma: evaluation, treatment challenges, and outcomes. *Explor Endocr Metab Dis.* 2024;1:218–33. <https://doi.org/10.37349/eemd.2024.00018>

Abstract

Pheochromocytomas (PCCs) and paragangliomas (PGLs; together PPGLs) are uncommon neuroendocrine tumors arising from adrenal medullary chromaffin cells and sympathetic/parasympathetic paraganglia. Though PPGLs predominate in adult populations, pediatric cases of PPGLs represent more aggressive disease outcomes with 12% being diagnosed as metastatic. Metastatic disease (spread to bone, lung, lymph nodes, or liver) occurs in a subset of PPGLs, ranging from 15% to 17% depending on the underlying pathogenic variants. Historically, pulmonary metastases present clinically as multiple small lesions; however, cases of PPGLs with innumerable small metastases (a miliary pattern) overwhelming lung parenchyma define a novel yet exceptionally challenging disease presentation. This pattern of pulmonary lesions upon treatment and/or cellular lysis may lead to both respiratory decompensation as well as prolific catecholamine release, incurring significant morbidity and mortality if not appropriately managed. Of the 2,649 PPGL patients enrolled in our protocol from January 1, 2000, to April 30, 2023, 500 had metastatic disease, 122 were children/adolescents, and 3 of the 122 children/adolescents had extensive

© The Author(s) 2024. This is an Open Access article licensed under a Creative Commons Attribution 4.0 International License (<https://creativecommons.org/licenses/by/4.0/>), which permits unrestricted use, sharing, adaptation, distribution and reproduction in any medium or format, for any purpose, even commercially, as long as you give appropriate credit to the original author(s) and the source, provide a link to the Creative Commons license, and indicate if changes were made.



pulmonary metastatic disease. All three adolescent patients with extensive pulmonary metastases had cluster 1 PPGLs and suffered hypoxemia (due to pulmonary metastases) leading to overactive hypoxia signaling and catecholamine-induced signs and symptoms [among them hypertension and/or tachyarrhythmia(s)]. Interventions including surgery, chemotherapy, and radiotherapy were pursued. Two patients achieved disease stability, while one patient succumbed to disease. Ultimately these divergent outcomes emphasize the importance of recognizing poor prognostic factors and aggressive disease early, to select appropriate treatments. Optimal management of these patients must consider complications of catecholamine excess and the profound influence of hypoxia. Herein, we describe three adolescent cases of extensive pulmonary metastatic PPGL and the unique clinical challenges faced in treating these tumors alongside relevant literature to provide guidance on appropriate interventions (ClinicalTrials.gov identifier: NCT00004847).

Keywords

Pheochromocytoma, paraganglioma, adolescent, pulmonary, metastases

Introduction

Pheochromocytomas (PCCs) and paragangliomas (PGLs; together PPGLs) are rare neuroendocrine tumors that arise from the medulla of the adrenal gland or extra-adrenal chromaffin tissue, respectively. Those arising from sympathetic paraganglia are often characterized by catecholamine production and secretion—often in excess—and catecholamine-induced signs and symptoms [1–3]. In contrast, head and neck PGLs (HNPGLs) found along the parasympathetic chains rarely secrete catecholamines [4, 5]. Although most PPGLs will not develop metastatic lesions, approximately 20% behave aggressively and ultimately develop metastatic disease influenced by the underlying pathogenic variant(s), tumor location, and size, as well as secretory status [6–11]. Metastatic lesions are commonly found in bones (64%), lungs (47%), lymph nodes (36%), and the liver (32%) [6, 12–17]. Lung lesions are usually found as solitary masses ranging from a few millimeters to several centimeters and are often surgically resected. When multiple pulmonary lesions are present, surgical resection cannot be attempted, but must be treated via systemic therapy.

Nonetheless, various therapeutic options must be considered when treating patients with extensive pulmonary metastatic disease as some treatments may be contraindicated. The presence of innumerable lung lesions can result in hypoxia, which can drive the progression of cluster 1 PPGLs. Within cluster 1 PPGLs the hypoxia signaling pathway is already overactive (see [Figure 1](#)) while also being a stimulus for further catecholamine release, resulting in adverse cardiovascular events and compensatory polycythemia [18–20]. Thus, treatment should be initiated in a monitored environment as rapid tumor cell lysis and consequent pulmonary edema can lead to catecholamine surges or respiratory decompensation respectively [21, 22]. Patients should also be serially monitored as treatment may suppress compensatory polycythemia/hematopoiesis. Therefore, chemotherapies or systemic radiotherapies must be rationally selected in these patients [23].

Catecholamine excess heightens morbidity and mortality. Nearly all PPGL patients experience hypertension (92%) while 10–20% suffer life-threatening complications (e.g., myocardial infarction, stroke, multiple organ failure) with adverse cardiovascular events being the main cause of death (up to 71%) [20, 24]. Therefore, treating both pediatric (< 18 years old) and adolescent (10 to 19 years old) metastatic PPGL with extensive pulmonary metastases presents clinical challenges (such as higher incidence of symptoms) which are discussed alongside demonstrative cases and relevant literature [9, 25, 26].

Case report

The case presentations for all patients are summarized below. For further information pertaining to biochemical laboratory data and the extent of tumor/metastatic involvement refer to [Tables 1, 2 and 3](#), and [Figures 2, 3 and 4](#), respectively. Alternatively, the patient cases are generally summarized in [Figure 5](#) (timeline).

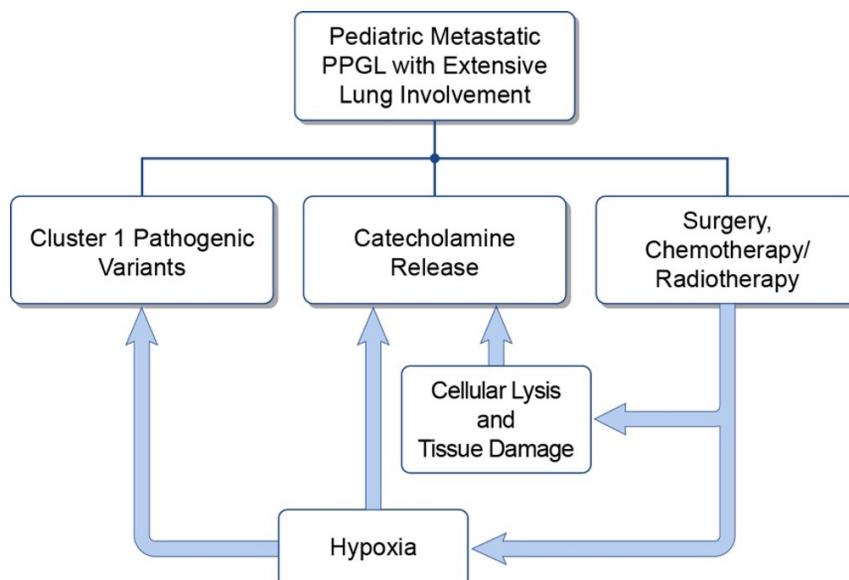


Figure 1. The interplay between hypoxia, catecholamine excess, and pulmonary tumor burden. PPGL: pheochromocytomas and paragangliomas

Table 1. Patient 1: serial biochemistries

Times the URL	3/12/2020 plasma	5/28/2021 plasma	9/24/2021 plasma	Normal values* pg/mL [nmol/L]
Normetanephrine	15.6 (1,743)	0.6 [0.52]	0.6 [0.55]	18–112 [< 0.90]
Metanephrine	1.5 (91)	U	U	12–61 [< 0.50]
Norepinephrine		0.8 [563]	0.5 [400]	112–750
Dopamine		U	0.9 [25]	0–29
Epinephrine		U	U	0–50
Chromogranin A	4.9 (453)		0.9 [80]	< 93

Elevated values are bolded. * Note fractionated plasma values (e.g., fractionated metanephrines) are provided in picograms per milliliter in parenthesis (pg/mL) while total values (e.g., total metanephrines) are provided in nanomoles per liter in brackets [nmol/L]. Blank cells indicate an absence of laboratory data for the respective time point. URL: upper reference limit; U: undetectable/below the lower limit of the reference range

Table 2. Patient 2: serial biochemistries

Times the URL	7/23/2019 urine	7/23/2019 plasma	9/13/2019 plasma	Normal values* pg/mL [µg/24h]
Normetanephrine	1.8 [683]	0.2 (25)	0.5 (58)	18–112 [103–390]
Metanephrine	1.1 [204]	0.4 (22)	0.3 (18)	12–61 [35–180]
Norepinephrine	0.7 [56]	0.3 (191)	0.3 (251)	112–750 [15–80]
Dopamine	1.2 [462]	U	U	0–29 [65–400]
Epinephrine	0.1 [1.7]	U	U	0–50 [< 21]
Chromogranin A		1.0 (92)		< 93]

Elevated values are bolded. * Note fractionated plasma values (e.g., fractionated metanephrines) are provided in picograms per milliliter in parenthesis (pg/mL) while 24-hour urine values are provided in micrograms over 24 hours in brackets [µg/24h]. Blank cells indicate an absence of laboratory data for the respective time point. URL: upper reference limit; U: undetectable/below the lower limit of the reference range

Table 3. Patient 3: serial biochemistries

Times the URL	08/11/2016 plasma	2/9/2017 plasma	02/10/2017 urine	3/23/2018 plasma	Normal values* pg/mL [µg/24h]
Normetanephrine	37.6 (4,209)	43.6 (4,883)	31.4 [12,238]	4.8 (538)	18–112 [103–390]
Metanephrine	U	U	U	U	12–61 [35–180]
Norepinephrine	9.9 (7,434)	13.2 (9,928)	25.9 [2,068]	1.6 (1,200)	112–750 [15–80]
Dopamine	U	1.1 (33)	0.2 [96]	U	0–29 [65–400]
Epinephrine	U	0.6 (29)	0.2 [4.1]	0.5 (23)	0–50 [< 21]
Chromogranin A	6.5 (605)	5.6 (520)		2.8 (263)	[< 93]

Elevated values are bolded. * Note fractionated plasma values (e.g., fractionated metanephrines) are provided in picograms per milliliter in parenthesis (pg/mL) while 24-hour urine values are provided in micrograms over 24 hours in brackets [µg/24h]. Blank cell indicates an absence of laboratory data for the respective time point. URL: upper reference limit; U: undetectable/below the lower limit of the reference range

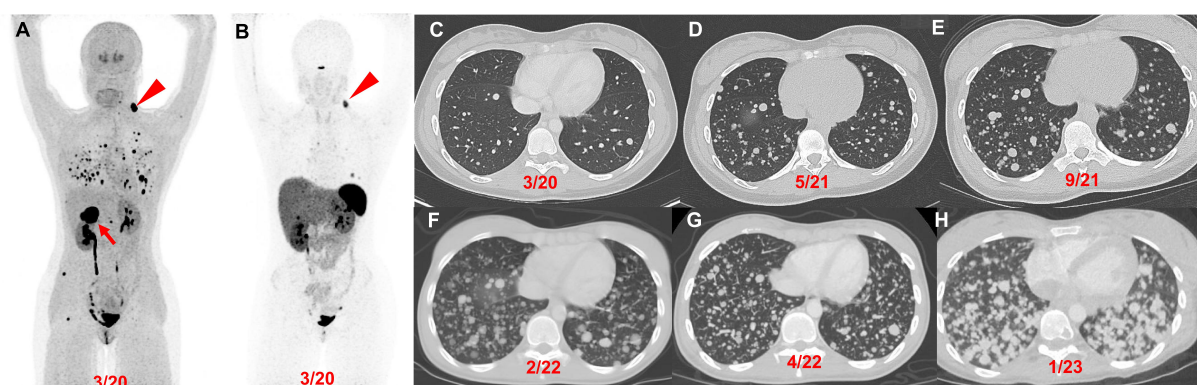


Figure 2. Patient 1 (14-year-old female, *VHL* pathogenic variant), serial images throughout the course of treatment: Anterior maximum intensity projection images of ^{18}F -FDOPA PET/CT (A) and ^{68}Ga -DOTATATE PET/CT (B) demonstrate a 4.4 cm right PCC (red arrow), left parapharyngeal neck mass (red arrowhead), and widespread metastatic lesions in the lungs and bones. Axial contrast CT images (C–H) in the same plane at various time points (03/2020, 05/2021, 09/2021, 02/2022, 04/2022, and 01/2023) show the patient's progression (increase in number of lung lesions and tumor volume) despite therapy (3 cycles of CVD between 12/2021 and 2/2022; 3 cycles of axitinib between 3/2022 and 10/2022; and pembrolizumab and axitinib between 10/2022 and 02/2023). CVD: cyclophosphamide, vincristine, and dacarbazine; PCC: pheochromocytoma

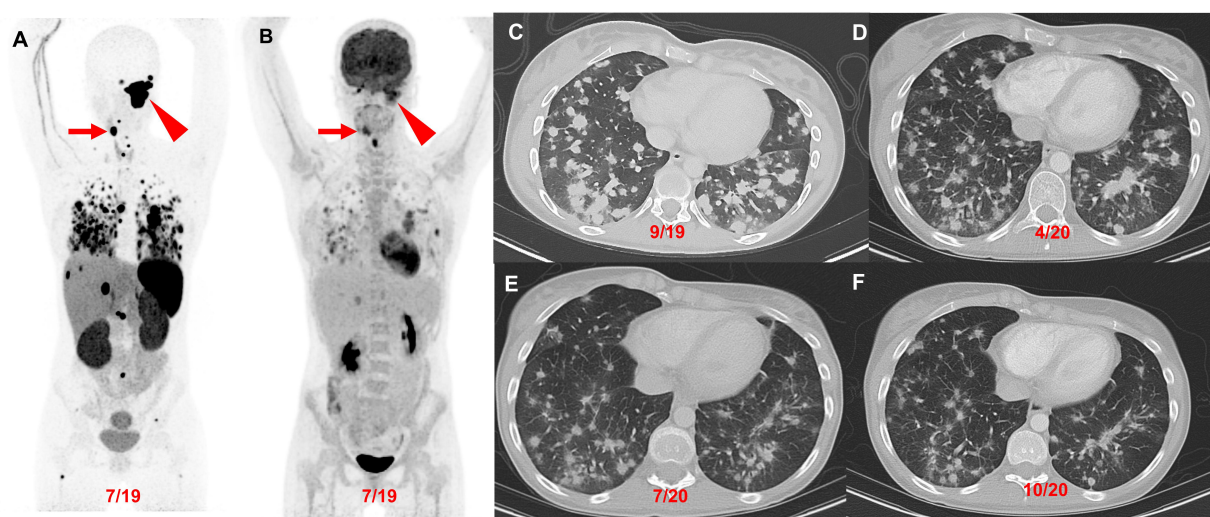


Figure 3. Patient 2 (23-year-old female, *SDHD* pathogenic variant), serial images throughout the course of treatment: Anterior maximum intensity projection images of ^{68}Ga -DOTATATE PET/CT (A) and ^{18}F -FDG PET/CT (B) demonstrate a 7.1 cm complex left jugular mass (red arrowhead) and a 2.5 cm right carotid body paraganglioma (red arrow) with widespread metastatic lesions in the lungs, mediastinum, liver, and bones. The axial contrast CT images (C–F) in the same plane at various time points (09/2019, 04/2020, 07/2020, and 10/2020) show the patient's response (decrease in number of lung lesions and tumor volume) after 4 cycles of CVD therapy (between 10/2019 and 03/2020) with resolution of hypoxemia. CVD: cyclophosphamide, vincristine, and dacarbazine

Patient 1: At the age of 12 (2018) the patient was found to have a solitary left neck PGL measuring 7.5 cm. At the age of 14 (2020), the patient had elevated plasma normetanephrine, chromogranin A, and metanephrine (15.6, 4.9, and 1.5 times the upper reference limit, URL, respectively; Table 1) with a recurrent left neck mass, right PCC, and significant pulmonary metastases (miliary pattern) on imaging. Following tumor resection of the 4.4 cm right PCC subsequent immunohistochemical (IHC) staining of the primary tumor was positive for synaptophysin, chromogranin, and S100 in surrounding sustentacular cells with a Ki-67 proliferation rate of 10% consistent with PGL. Germline genetic testing confirmed a *VHL* pathogenic variant (*VHL* c.250G>T, p.Val84Leu).

The patient's biochemistries normalized post-operatively, but at the age of 15 (2021), she developed hypoxemia requiring (2L) of supplemental oxygen and was found to have a progression of extensive multifocal lung metastases (Table 1, Figure 2). She was then treated with 3 cycles of cyclophosphamide, vincristine, and dacarbazine (CVD), complicated by multiple cytopenias and a 5-kg weight loss with progression of disease on imaging. Her disease progressed despite being transitioned to axitinib (3 mg, twice daily for 7 months) and then pembrolizumab (25 mg, twice daily for 5 months) (Figure 2). She was transitioned to hospice care and succumbed to disease at the age of 17 (2023).

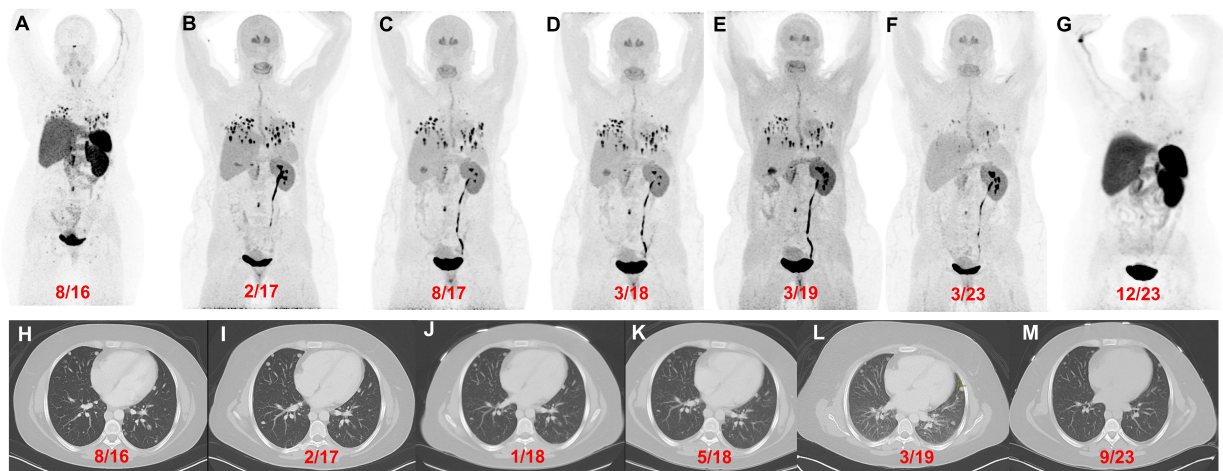


Figure 4. Patient 3 (26-year-old female, *VHL* pathogenic variant), serial images throughout the course of treatment: Anterior maximum intensity projection images of ^{68}Ga -DOTATATE PET/CT (A and G) and ^{18}F -FDOPA PET/CT (B–F) with a history of a right adrenalectomy (4.2 cm), right nephrectomy, and left periaortic- and aortocaval mass resection in 2016 [resection(s) prior to imaging] demonstrate widespread metastatic lesions in the lungs, retroperitoneal adenopathy, and a few bone metastases. ^{18}F -FDOPA PET/CT images before (B), during (C), and after (D) treatment with CAPTEM. ^{18}F -FDOPA PET/CT (E and F) imaging demonstrate disease stability with temozolomide monotherapy. ^{18}F -FDOPA PET/CT on 03/2023 (F) shows a significant decrease in the number of lung lesions and a reduction in tumor volume compared to prior imaging. The axial contrast CT images (H–M) in the same plane at various time points (08/2016, 02/2017, 01/2018, 05/2018, 03/2019, and 09/2023) show progression of disease prior to chemotherapy (H and I) followed by stable disease (J–L) and a marginal decrease in tumor size(s) on 09/2023 (compared to 03/2019). However, a more robust response was appreciated on ^{18}F -FDOPA PET/CT [02/2017 (B) vs 03/2023 (F)] and ^{68}Ga -DOTATATE PET/CT [08/2016 (A) vs 12/2023 (G)]

Patient Clinical Courses

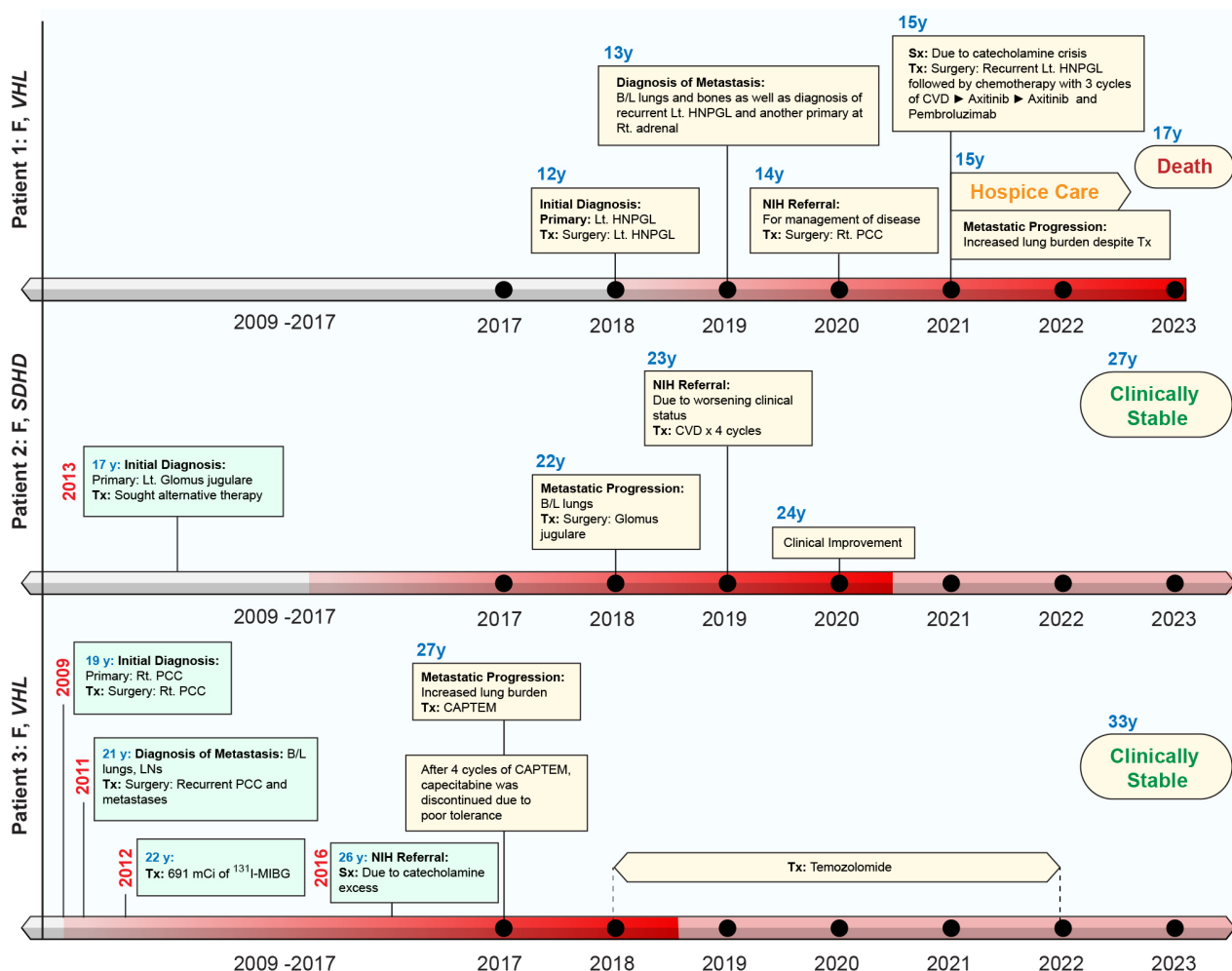


Figure 5. Patient clinical courses. The intensity of red color in the timelines on the x-axis represents the disease status. The darker shade represents worse disease status. B/L: bilateral; CAPTEM: capecitabine and temozolomide; CVD: cyclophosphamide, vincristine, dacarbazine; HNPGL: head and neck paraganglioma; ^{131}I -MIBG: ^{131}I -metaiodobenzylguanidine; LNs: lymph nodes; Lt: left; PCC: pheochromocytoma; PPGL: pheochromocytoma and paraganglioma; Rt: right; Sx: symptoms; Tx: treatment

Patient 2: At the age of 17 (2013) the patient was diagnosed with a left glomus jugulare PGL. After 5 years of pursuing alternative treatment, she presented to an outside institution at the age of 22 (2018) with visible outgrowth from her left ear with bleeding and was found to have an extension of the primary tumor, a right carotid body tumor, and extensive pulmonary metastases (miliary pattern) (Figure 3). She then underwent partial resection/debulking of the left glomus jugulare PGL (2018). IHC staining of the tumor was positive for synaptophysin, chromogranin, and S100 in surrounding sustentacular cells consistent with PGL. Genetic testing of the primary tumor revealed a pathogenic variant in *SDHD* c.124_127delinsATA (*SDHD* p. Glu42Ilefs*44).

The patient presented to our institution at the age of 23 (2019) and was found to have elevated urine normetanephrine, metanephrine, and dopamine (1.8, 1.1, and 1.2 times the URL, respectively; Table 2) and soon developed hypoxemia requiring (1L) supplemental oxygen. She responded to treatment with 4 cycles of CVD with reduced pulmonary tumor burden and resolution of hypoxemia (Figure 3). She then discontinued treatment and gave birth to two children at the age of 26 and is clinically stable.

Patient 3: At the age of 19 (2009) the patient was found to have a right 4.2 cm PCC upon evaluation for hypertension and headaches. Following resection, IHC staining was positive for synaptophysin, chromogranin, and S100 in surrounding sustentacular cells consistent with PCC. Germline genetic testing of the primary tumor (PCC) confirmed a *VHL* pathogenic variant (*VHL* c.439C>G, p. Leu147Val). At the age of 21 (2011), with elevated plasma biochemistries and metastatic PGL noted on ¹²³I-metaiodobenzylguanidine (¹²³I-mIBG) scintigraphy she underwent tumor resection (left periaortic tumor resection, right nephrectomy, and aortocaval mass resection) followed by ¹³¹I-mIBG radiotherapy (691 mCi total in 1 year).

The patient was referred to our institution at the age of 26 (2016) with signs and symptoms of catecholamine excess and hypoxemia requiring (2–3L) supplemental oxygen and was found to have elevated plasma norepinephrine and normetanephrine (37.6 and 9.9 times the URL respectively; Table 3) with extensive pulmonary metastases on imaging metastases (miliary pattern) (Figure 4). She was then treated with 4 cycles of capecitabine and temozolomide (CAPTEM, in 2017) then temozolomide (180 mg twice daily PO for 5 days every 28 days) for 6 years until the age of 32 (2022). At age 33 (2023) she was clinically stable and had a slight reduction in tumor burden (Figure 4).

Discussion

This study describes three female adolescent patients with metastatic PPGL and extensive lung involvement. Each patient had catecholamine excess and hypoxemia with common complications (e.g., hypertension) [3, 20, 24]. In this small series, surgical intervention of isolated PPGLs was the first-line treatment in all patients followed by adjuvant chemotherapy and/or systemic radiotherapy. Two patients had a favorable outcome, while one succumbed to metastatic disease. Thus, early intervention that considers the consequences of tumor progression associated with severe hypoxia and catecholamine excess is important in these cases. This is especially true when considering how these conditions are interrelated (Figure 1), as hypoxia worsens catecholamine release and drives the progression of PPGLs (or other cancers) with pseudohypoxia-associated pathogenic variants (like *VHL* and *SDHD*) [27]. As such, any systemic therapy must be carefully selected to avoid further complications when a risk of rapid tumor lysis is present (leading to pulmonary edema and respiratory failure and/or concurrent catecholamine surges) and/or to avoid treatment-induced pulmonary sequelae (like lung fibrosis) [23, 27, 28]. Therefore, all patients with metastatic disease, including patients with extensive pulmonary metastases, should have guideline-compliant and frequent re-evaluation consisting of (1) measurement of plasma or urine metanephrines and (2) anatomic (e.g., CT) as well as functional imaging [e.g., most often ⁶⁸Ga-DOTA(0)-Tyr(3)-octreotate (⁶⁸Ga-DOTATATE PET/CT)] [22, 29–31].

Pediatric hereditary PPGL

Pediatric cases of PPGL are exceptionally rare with an incidence of 0.45 cases per million in childhood/adolescence as opposed to 4.6 cases per million in adults which is a 10-fold greater incidence [2, 32, 33]. The most common cause of PPGLs in children and adolescents are pathogenic variants in cluster 1 genes: *VHL*

(27–51%) and *SDHD* (8–10%). These PPGL variants are quite prevalent and on average present at the age of 9 (for *VHL*-associated tumors) and 10 (for *SDHD*-associated tumors), respectively [32–38]. In children, metastases may be synchronous (present at the time of diagnosis), but are more likely to develop over time, further emphasizing the need for lifetime surveillance so that providers can identify the signs and symptoms of progressive disease [32]. Recognition of these indicators allows for appropriate selection of treatment; the risk of metastasis in children (due to disease going undetected) is higher than in adults and may have catastrophic implications if stored catecholamines are suddenly released (by surgery, induction of anesthesia, and/or interfering medications) [33]. Poor prognostic indicators include extra-adrenal tumor location (PGL compared to PCC), size (≥ 5 cm) at presentation, familial inheritance (in these cases often cluster 1A PPGLs), non-secretory status (as tumors are considered less differentiated), metastasis (especially metastases to the lung and liver), and metastatic interval (patients with a shorter metastatic interval are younger and more likely to have soft tissue metastases) [13, 16, 33, 38–40]. In contrast, favorable prognostic indicators include cluster 2 PPGLs (e.g., well-differentiated and often lower grade) and small tumors (preferably found in the adrenal gland) [13, 16, 32, 38–40].

Evaluation and screening

Evaluation for PPGL in pediatric patients tends to be prompted by symptoms (hypertension: 64–93%, headache: 39–95%, diaphoresis: 90%, palpitations: 53%) in 90% of patients or by detection of an incidentally noted mass [2, 13]. Subsequent biochemical analysis may be performed—taking care to avoid interfering agents—with plasma metanephrines, which are the most sensitive, or urinary metanephrines which are less sensitive but avoid the difficulties of venipuncture in children [3, 29, 41, 42]. Beyond metanephrine and normetanephrine, plasma 3-methoxytyramine (3-MTY, the metabolite of dopamine) or chromogranin A may reveal clinically silent/non-secretory tumors [3, 41, 43–46].

Whole-body imaging (e.g., CT and/or MRI) should be obtained when PPGL(s) are suspected with CT providing superior diagnostic sensitivity in identifying metastatic pulmonary lesions [13, 47]. Alternatively, MRI avoids radiation exposure but often requires sedation and endotracheal intubation while gadolinium (if used) has been shown to accumulate in the CNS with unclear significance [35]. The imaging modality (CT vs MRI) with the best benefit and least risk should be chosen on a case-by-case basis.

In general, anatomic imaging usually precedes functional imaging; but is lacking in its ability to characterize small nodules or bony lesions [47]. Functional imaging in PPGLs utilizes radiopharmaceuticals that target functional receptors/proteins for precise localization of these tumors within the body [13, 23, 47–49]. Radiopharmaceuticals such as ^{68}Ga -DOTATATE, ^{18}F -fludopa (^{18}F -FDOPA), ^{18}F -fluorodopamine (^{18}F -FDA), and ^{18}F -fluorodeoxyglucose (^{18}F -FDG) are used for PPGL imaging. However, ^{68}Ga -DOTATATE, along with the non-specific radiopharmaceutical ^{18}F -FDG are used most often to screen for PPGL [47, 49, 50]. Particularly, ^{68}Ga -DOTATATE PET/CT has excellent sensitivity in cluster 1A (e.g., *SDHx*) PPGLs including in pediatric patients, HNPPGLs, and metastatic lesions [10, 17, 49–60]. In comparison, ^{18}F -FDOPA PET/CT has excellent sensitivity for tumors in cluster 1B (*VHL*, *EPAS1/HIF2A*) and cluster 2 (*RET*, *MAX*, *NF1*, etc.) PPGLs and apparently sporadic PCC [61–67]. ^{123}I -mIBG scintigraphy is mainly performed along with ^{68}Ga -DOTATATE to establish whether treatment with ^{131}I -mIBG or $^{177}\text{Lu}/^{225}\text{Ac}$ -DOTATATE (respectively) would be suitable [23, 48–52, 68].

PET imaging is often used as a surrogate for invasive procedures in patients with metastatic or progressive disease. Where surgery or biopsy is avoided for fear of inducing the release of stored catecholamines resulting in catecholamine-induced hypertensive crisis, especially in children [24, 33]. Patients who can undergo resection or biopsy qualify for histopathological analysis to verify molecular pathogenesis active in tissues through IHC staining (with biochemical markers such as chromogranin, synaptophysin, and Ki-67). A component of this analysis may include the Grading Systems for Adrenal PCC and PGL (GAPP) and/or the PCC of the Adrenal Gland Scales Score (PASS) validation systems which assist in the classification of metastatic PPGL. However, both systems have shown a lack of utility in the clinical environment displaying limited predictive ability [8].

Treatment

Treatment consists of operative and non-operative interventions. Notably, adrenoceptor blockade is advisable in secretory tumors before any intervention (operative or non-operative) that may cause tumor disruption. α -Adrenoceptor blocking agents followed by β -adrenoceptor blocking agents should be administered to avoid unbalanced adrenoceptor blockade which may precipitate (or worsen) hypertension or tachyarrhythmias and lead to PPGL crisis [1].

In operable patients with PPGL, resection is the first line of treatment for solitary lesions and is sometimes indicated for lesions causing mass effect or to decrease catecholamine excess associated with various symptoms/signs. Therefore, surgery (in those that qualify) collectively increases overall survival by 24% [69].

In inoperable patients with PPGL (due to poor performance status or location, for example, HNPGs abutting eloquent neurologic structures, thus precluding surgery) systemic and/or local radiotherapies are the treatments of choice [33, 34].

Rate-of-growth (fast versus slow growing) in progressive disease, guides subsequent management. In more rapidly progressive inoperable disease, patients are most often treated with CVD chemotherapy, followed by tyrosine kinase inhibitors (TKIs), and finally, in some selected patients, immunotherapy [22, 69]. Immunotherapy using pembrolizumab, a humanized anti-PD-1 receptor antibody, is being investigated in clinical trials evaluating patients with cluster 1 and 2 tumors with PD-L1 expression but must be further reviewed [69–71]. Chemotherapy can elicit a response (defined as decreased or normalized blood pressure/decreased number and dosage of antihypertensive medications and/or reduced tumor size) in a few weeks as opposed to radionuclide therapies that may require 6–12 months [69]. CVD chemotherapy is usually the first line of treatment and is especially effective in patients with cluster 1 tumors (complete response: 11%, partial response 44%) [6, 69]. Chemotherapy with temozolomide (TMZ) is a common second line of treatment, due to its efficacy as a short-term treatment, or in conjunction with capecitabine (CAPTEM), which has been shown to prolong survival in advanced neuroendocrine tumors, but requires further study in PPGLs [70, 71]. TKIs are also being studied in the treatment of PPGL and may be an alternative if CVD and/or CAPTEM are ineffective or implemented as a first-line therapy [72–74]. Current TKIs under ongoing investigation include: sunitinib, pazopanib, cabozantinib, axitinib, and anlotinib which have been shown to elicit very promising responses in various cohorts overall [73, 75, 76]. Notably, both CVD and systemic radiotherapy may lead to cell lysis, consequent catecholamine release, and associated complications; therefore, close monitoring upon initiation of treatment is advisable.

In more indolent inoperable disease, patients are treated with targeted peptide receptor radionuclide therapies (^{131}I -mIBG: low-specific-activity or high-specific-activity) or ^{177}Lu -DOTATATE (Lutathera[®]) if their corresponding functional imaging (^{123}I -mIBG or ^{68}Ga -DOTATATE) demonstrates radiotracer uptake within their tumors. Previously, some treatment options included either high-specific-activity ^{131}I -mIBG or ^{177}Lu -DOTATATE (Lutathera[®]). Patients with sufficient bone marrow reserve, high catecholamine burden, and avidity on ^{123}I -mIBG scintigraphy qualify for the FDA-approved high-specific-activity ^{131}I -mIBG therapy (Azedra[®]), however, its production has been discontinued [23, 68, 77]. So, in such cases, low-specific-activity ^{131}I -mIBG therapy is a suitable alternative [23, 68]. Lutathera[®] (^{177}Lu -DOTATATE) is best suited for patients who are avid on ^{68}Ga -DOTATATE or ^{64}Cu -DOTATATE [23, 58, 68]. It is often well-tolerated with a disease control rate of up to 90% and can be given to patients greater than 65 years of age or patients with compromised bone marrow reserve [23, 68]. Thus, in hypoxic patients with disease that is avid on both studies (^{123}I -mIBG and ^{68}Ga -DOTATATE), perhaps Lutathera[®] may be preferable as it imposes less of a risk in suppressing erythropoiesis (an essential compensation in hypoxic patients), especially if high ^{131}I -mIBG doses are considered for treatment [23]. However, endocrinopathies may be seen with Lutathera[®] [78, 79]. Other options for inoperable patients with ^{68}Ga -DOTATATE avid disease include somatostatin analogs, such as lanreotide or octreotide, often in those with cluster 1 tumors, especially *SDHx* PPGLs [80–82]. Currently, a phase II trial evaluating lanreotide in inoperable/metastatic PPGL is ongoing (LAMPARA, NCT03946527) and its results would be pivotal in determining its efficacy in this cohort.

Therefore, in short, these imaging modalities have a two-fold benefit as they bind to and highlight somatostatin receptors upon tumors, allowing them to be imaged, while simultaneously demonstrating that therapy directed toward somatostatin receptors is effective [7, 82–84]. Alternatively, if patients progress on chemotherapy and radionuclide therapy, or cannot qualify for radionuclide therapy (because the disease is not avid on ^{123}I -mIBG scintigraphy or ^{68}Ga -DOTATATE PET), these patients may be treated with TKIs or chemotherapy with CVD or TMZ, as described above.

Avidity on various imaging modalities is a significant indicator of treatment viability and certain pathogenic variants have a higher incidence of positive response on certain therapies. CVD therapy has been shown to elicit continued tumor reduction in *SDHB*-mutated tumors. This positive response with CVD can also be extended to subsequent treatment with TMZ which has higher susceptibility due to increased methylation in the O^6 -methylguanine-DNA methyltransferase (MGMT) promoter region in *SDHB*-mutated tumors [6]. As such, a similar response is elicited in *SDHx* pathogenic variants due to similar pseudohypoxia-driven increases in succinate and DNA hypermethylation [6]. For those patients with fast-growing metastatic disease *SDHx* pathogenic variants that demonstrate sensitivity to ^{68}Ga -DOTATATE PET/CT usually have a positive response to somatostatin analogs [23]. A trial at the NIH evaluating patients that underwent treatment with Lutathera[®] demonstrated a 6-month progression-free survival of 19.1 months (22.7 in sporadic cohorts, and 15.4 in *SDHx* cohorts) further demonstrating that differences in treatment efficacy can be observed with different pathogenic variants [23, 85]. If these, more therapeutic, treatment options do not suffice, experimental options (as discussed below) can be pursued.

On the horizon

Currently, promising therapies include antagonists of the hypoxia signaling pathway (such as belzutifan), which is overactive in cluster 1 pathogenic tumors, PRRT with somatostatin antagonist, and α -emitter based targeted radiotherapy [86–89]. Clinical trials assessing the utility of belzutifan (NCT04924075), a HIF-2 α inhibitor currently approved for the treatment of tumors harboring a *VHL* pathogenic variant, are ongoing [86–88]. Belzutifan could be a promising treatment modality carefully selected for patients with lung metastases given its efficacy, tolerability, and mechanism as it opposes the overactive hypoxia signaling pathway. Nevertheless, caution must be exercised in patients with hypoxemia as belzutifan decreases erythropoietin production resulting in anemia and potentially worsening tissue hypoxia [87, 88, 90, 91]. Providers that encounter non-hypoxic pediatric patients with lung metastases from cluster 1 tumors and suitable bone marrow reserve should consider enrollment on a clinical trial if available. Alternatively, an initial pilot study with ^{225}Ac -DOTATATE suggests that α -emitter therapy could control metastatic disease and improve the quality of life in PPGL patients [23, 89].

Conclusions

Pediatric patients with PPGL are predisposed to more aggressive disease presentations (multifocal/metastatic, extra-adrenal, and recurrent) over their lifespan compared to adult patients. If PPGLs metastasize to the lungs the risk of mortality may increase, especially when lesions are innumerable and secretory, as represented by patient 3 presented in this report. Despite these clinical challenges, by rationally considering the context of hypoxia, catecholamine excess, genetic background, and age, early intervention can minimize morbidity and offer a favorable prognosis.

Abbreviations

CAPTEM: capecitabine and temozolomide

CVD: cyclophosphamide, vincristine, and dacarbazine

HNPGs: head and neck paragangliomas

IHC: immunohistochemical

PCC: pheochromocytoma

PGL: paraganglioma

PPGL: pheochromocytoma and paraganglioma

TKIs: tyrosine kinase inhibitors

TMZ: chemotherapy with temozolomide

URL: upper reference limit

Declarations

Author contributions

KMC and KP: Conceptualization, Investigation, Writing—original draft, Writing—review & editing. MAN: Conceptualization, Investigation, Writing—original draft, Writing—review & editing, Supervision. AJ, MP, AL, and TP: Investigation, Data curation. ST: Writing—review & editing. MJMK: Investigation. ASA, AD, AC, JG, and JDR: Investigation, Writing—review & editing. All authors read and approved the submitted version.

Conflicts of interest

Prof. Karel Pacak is the Editor-in-Chief of Exploration of Endocrine and Metabolic Diseases, but he was not involved in the decision-making or review process of this manuscript.

Ethical approval

This study was part of a protocol (NCT00004847) approved by the National Institutes of Health Institutional Review Board (Protocol: 00-CH-0093).

Consent to participate

Informed consent to participate in the study was obtained from the parents (and or guardians) of the participants.

Consent to publication

Informed consent to publish this article was obtained from the parents (and or guardians) of the participants.

Availability of data and materials

The datasets that support the findings of this study are available from the corresponding author upon reasonable request.

Funding

This study was funded by the National Institutes of Health [Z1AHD008735]. This work was supported by the Intramural Research Program of the National Institutes of Health, *Eunice Kennedy Shriver* National Institute of Child Health and Human Development. The funders had no role in study design, data collection and analysis, decision to publish, or preparation of the manuscript.

Copyright

© The Author(s) 2024.

References

1. Lenders JWM, Eisenhofer G, Mannelli M, Pacak K. Pheochromocytoma. *Lancet*. 2005;366:665–75. [DOI] [PubMed]
2. Pamporaki C, Hamplova B, Peitzsch M, Prejbisz A, Beuschlein F, Timmers HJLM, et al. Characteristics of Pediatric vs Adult Pheochromocytomas and Paragangliomas. *J Clin Endocrinol Metab*. 2017;102:1122–32. [DOI] [PubMed] [PMC]
3. Eisenhofer G, Pamporaki C, Lenders JWM. Biochemical Assessment of Pheochromocytoma and Paraganglioma. *Endocr Rev*. 2023;44:862–909. [DOI] [PubMed]

4. Richter S, Qiu B, Ghering M, Kunath C, Constantinescu G, Luths C, et al. Head/neck paragangliomas: focus on tumor location, mutational status and plasma methoxytyramine. *Endocr Relat Cancer*. 2022; 29:213–24. [DOI] [PubMed] [PMC]
5. Van Duinen N, Corssmit EPM, De Jong WHA, Brookman D, Kema IP, Romijn JA. Plasma levels of free metanephrines and 3-methoxytyramine indicate a higher number of biochemically active HNPGL than 24-h urinary excretion rates of catecholamines and metabolites. *Eur J Endocrinol*. 2013;169:377–82. [DOI] [PubMed]
6. Nölting S, Grossman A, Pacak K. Metastatic Pheochromocytoma: Spinning Towards More Promising Treatment Options. *Exp Clin Endocrinol Diabetes*. 2019;127:117–28. [DOI] [PubMed] [PMC]
7. Ilanchezhian M, Jha A, Pacak K, Del Rivero J. Emerging Treatments for Advanced/Metastatic Pheochromocytoma and Paraganglioma. *Curr Treat Options Oncol*. 2020;21:85. [DOI] [PubMed] [PMC]
8. Nölting S, Ullrich M, Pietzsch J, Ziegler CG, Eisenhofer G, Grossman A, et al. Current Management of Pheochromocytoma/Paraganglioma: A Guide for the Practicing Clinician in the Era of Precision Medicine. *Cancers (Basel)*. 2019;11:1505. [DOI] [PubMed] [PMC]
9. Jochmanova I, Abcede AMT, Guerrero RJS, Malong CLP, Wesley R, Huynh T, et al. Clinical characteristics and outcomes of *SDHB*-related pheochromocytoma and paraganglioma in children and adolescents. *J Cancer Res Clin Oncol*. 2020;146:1051–63. [DOI] [PubMed] [PMC]
10. Jha A, De Luna K, Balili CA, Millo C, Paraiso CA, Ling A, et al. Clinical, Diagnostic, and Treatment Characteristics of *SDHA*-Related Metastatic Pheochromocytoma and Paraganglioma. *Front Oncol*. 2019;9:53. [DOI] [PubMed] [PMC]
11. Kuo MJM, Nazari MA, Jha A, Pacak K. Pediatric Metastatic Pheochromocytoma and Paraganglioma: Clinical Presentation and Diagnosis, Genetics, and Therapeutic Approaches. *Front Endocrinol (Lausanne)*. 2022;13:936178. [DOI] [PubMed] [PMC]
12. Flidner SMJ, Lehnert H, Pacak K. Metastatic paraganglioma. *Semin Oncol*. 2010;37:627–37. Erratum in: *Semin Oncol*. 2011;38:467. [DOI] [PubMed] [PMC]
13. Pacak K. New Biology of Pheochromocytoma and Paraganglioma. *Endocr Pract*. 2022;28:1253–69. [DOI] [PubMed] [PMC]
14. Ayala-Ramirez M, Feng L, Johnson MM, Ejaz S, Habra MA, Rich T, et al. Clinical risk factors for malignancy and overall survival in patients with pheochromocytomas and sympathetic paragangliomas: primary tumor size and primary tumor location as prognostic indicators. *J Clin Endocrinol Metab*. 2011;96:717–25. [DOI] [PubMed]
15. Ayala-Ramirez M, Palmer JL, Hofmann M, De la Cruz M, Moon BS, Waguespack SG, et al. Bone metastases and skeletal-related events in patients with malignant pheochromocytoma and sympathetic paraganglioma. *J Clin Endocrinol Metab*. 2013;98:1492–7. [DOI] [PubMed] [PMC]
16. Hamidi O, Young WF Jr, Iñiguez-Ariza NM, Kittah NE, Gruber L, Bancos C, et al. Malignant Pheochromocytoma and Paraganglioma: 272 Patients Over 55 Years. *J Clin Endocrinol Metab*. 2017; 102:3296–305. [DOI] [PubMed] [PMC]
17. Jha A, Patel M, Ling A, Shah R, Chen CC, Millo C, et al. Diagnostic performance of [⁶⁸Ga]DOTATATE PET/CT, [¹⁸F]FDG PET/CT, MRI of the spine, and whole-body diagnostic CT and MRI in the detection of spinal bone metastases associated with pheochromocytoma and paraganglioma. *Eur Radiol*. 2024; 34:6488–98. [DOI] [PubMed] [PMC]
18. Kluckova K, Tennant DA. Metabolic implications of hypoxia and pseudohypoxia in pheochromocytoma and paraganglioma. *Cell Tissue Res*. 2018;372:367–78. [DOI] [PubMed] [PMC]
19. Jochmanová I, Yang C, Zhuang Z, Pacak K. Hypoxia-inducible factor signaling in pheochromocytoma: turning the rudder in the right direction. *J Natl Cancer Inst*. 2013;105:1270–83. [DOI] [PubMed] [PMC]

20. Nazari MA, Rosenblum JS, Haigney MC, Rosing DR, Pacak K. Pathophysiology and Acute Management of Tachyarrhythmias in Pheochromocytoma: *JACC Review Topic of the Week*. *J Am Coll Cardiol*. 2020; 76:451–64. [DOI] [PubMed] [PMC]
21. Jimenez C, Xu G, Varghese J, Graham PH, Campbell MT, Lu Y. New Directions in Treatment of Metastatic or Advanced Pheochromocytomas and Sympathetic Paragangliomas: an American, Contemporary, Pragmatic Approach. *Curr Oncol Rep*. 2022;24:89–98. [DOI] [PubMed]
22. Fishbein L, Del Rivero J, Else T, Howe JR, Asa SL, Cohen DL, et al. The North American Neuroendocrine Tumor Society Consensus Guidelines for Surveillance and Management of Metastatic and/or Unresectable Pheochromocytoma and Paraganglioma. *Pancreas*. 2021;50:469–93. [DOI] [PubMed]
23. Pacak K, Taieb D, Lin FI, Jha A. Approach to the Patient: Concept and Application of Targeted Radiotherapy in the Paraganglioma Patient. *J Clin Endocrinol Metab*. 2024;109:2366–88. [DOI] [PubMed] [PMC]
24. Nazari MA, Hasan R, Haigney M, Maghsoudi A, Lenders JWM, Carey RM, et al. Catecholamine-induced hypertensive crises: current insights and management. *Lancet Diabetes Endocrinol*. 2023;11:942–54. Erratum in: *Lancet Diabetes Endocrinol*. 2024;12:e1. [DOI] [PubMed]
25. Pham TH, Moir C, Thompson GB, Zarroug AE, Hamner CE, Farley D, et al. Pheochromocytoma and paraganglioma in children: a review of medical and surgical management at a tertiary care center. *Pediatrics*. 2006;118:1109–17. [DOI] [PubMed]
26. De Tersant M, Généré L, Freyçon C, Villebasse S, Abbas R, Barlier A, et al. Pheochromocytoma and Paraganglioma in Children and Adolescents: Experience of the French Society of Pediatric Oncology (SFCE). *J Endocr Soc*. 2020;4:bvaa039. [DOI] [PubMed] [PMC]
27. Reiterer M, Colaço R, Emrouznejad P, Jensen A, Rundqvist H, Johnson RS, et al. Acute and chronic hypoxia differentially predispose lungs for metastases. *Sci Rep*. 2019;9:10246. Erratum in: *Sci Rep*. 2020;10:1627. [DOI] [PubMed] [PMC]
28. Takabatake N, Arao T, Sata M, Abe S, Inoue S, Shibata Y, et al. Involvement of pulmonary endothelial cell injury in the pathogenesis of pulmonary fibrosis: clinical assessment by ¹²³I-MIBG lung scintigraphy. *Eur J Nucl Med Mol Imaging*. 2005;32:221–8. [DOI] [PubMed]
29. Giordano A, Calcagni ML, Rossi B, Rufini V, Fuso L, Valente S, et al. Use of metaiodobenzylguanidine (MIBG) in pneumology. *Q J Nucl Med*. 1995;39:49–54. [PubMed]
30. Phelps TE, Del Rivero J, Chertow DS, Rosing D, Pacak K, Lin FI. Managing Catecholamine Release Syndrome During and Following Lu-177-DOTATATE in High-Risk Pheochromocytoma Patients. *JCEM Case Rep*. 2024;2:luae049. [DOI] [PubMed] [PMC]
31. Lenders JWM, Duh QY, Eisenhofer G, Gimenez-Roqueplo AP, Grebe SKG, Murad MH, et al. Pheochromocytoma and paraganglioma: an endocrine society clinical practice guideline. *J Clin Endocrinol Metab*. 2014;99:1915–42. Erratum in: *J Clin Endocrinol Metab*. 2023;108:e200. [DOI] [PubMed]
32. Casey RT, Hendriks E, Deal C, Waguespack SG, Wiegering V, Redlich A, et al. International consensus statement on the diagnosis and management of phaeochromocytoma and paraganglioma in children and adolescents. *Nat Rev Endocrinol*. 2024; [Epub ahead of print]. Erratum in: *Nat Rev Endocrinol*. 2024. [DOI] [PubMed]
33. Taieb D, Nölting S, Perrier ND, Fassnacht M, Carrasquillo JA, Grossman AB, et al. Management of phaeochromocytoma and paraganglioma in patients with germline *SDHB* pathogenic variants: an international expert Consensus statement. *Nat Rev Endocrinol*. 2024;20:168–84. [DOI] [PubMed]
34. Taieb D, Wanna GB, Ahmad M, Lussey-Lepoutre C, Perrier ND, Nölting S, et al. Clinical consensus guideline on the management of phaeochromocytoma and paraganglioma in patients harbouring germline *SDHD* pathogenic variants. *Lancet Diabetes Endocrinol*. 2023;11:345–61. [DOI] [PubMed]
35. Nazari MA, Jha A, Kuo MJM, Patel M, Prodanov T, Rosenblum JS, et al. Paediatric phaeochromocytoma and paraganglioma: A clinical update. *Clin Endocrinol (Oxf)*. 2024;101:446–54. [DOI] [PubMed]

36. Turkova H, Prodanov T, Maly M, Martucci V, Adams K, Widimsky J Jr, et al. Characteristics and Outcomes of Metastatic *SDHB* and Sporadic Pheochromocytoma/Paraganglioma: An National Institutes of Health Study. *Endocr Pract*. 2016;22:302–14. [DOI] [PubMed] [PMC]
37. Seabrook A, Vasudevan A, Neville K, Gerstl B, Benn D, Smith J, et al. Genotype-phenotype correlations in paediatric and adolescent phaeochromocytoma and paraganglioma: a cross-sectional study. *Arch Dis Child*. 2024;109:201–8. [DOI] [PubMed]
38. Barontini M, Levin G, Sanso G. Characteristics of pheochromocytoma in a 4- to 20-year-old population. *Ann N Y Acad Sci*. 2006;1073:30–7. [DOI] [PubMed]
39. Waguespack SG, Rich T, Grubbs E, Ying AK, Perrier ND, Ayala-Ramirez M, et al. A current review of the etiology, diagnosis, and treatment of pediatric pheochromocytoma and paraganglioma. *J Clin Endocrinol Metab*. 2010;95:2023–37. [DOI] [PubMed]
40. Bausch B, Wellner U, Bausch D, Schiavi F, Barontini M, Sanso G, et al. Long-term prognosis of patients with pediatric pheochromocytoma. *Endocr Relat Cancer*. 2013;21:17–25. [DOI] [PubMed]
41. Eisenhofer G, Lenders JWM, Goldstein DS, Mannelli M, Csako G, Walther MM, et al. Pheochromocytoma catecholamine phenotypes and prediction of tumor size and location by use of plasma free metanephrines. *Clin Chem*. 2005;51:735–44. [DOI] [PubMed]
42. Mei L, Khurana A, Al-Juhaishi T, Faber A, Celi F, Smith S, et al. Prognostic Factors of Malignant Pheochromocytoma and Paraganglioma: A Combined SEER and TCGA Databases Review. *Horm Metab Res*. 2019;51:451–7. Erratum in: *Horm Metab Res*. 2019;51:e2. [DOI] [PubMed]
43. Eisenhofer G, Lenders JWM, Siegert G, Bornstein SR, Friberg P, Milosevic D, et al. Plasma methoxytyramine: a novel biomarker of metastatic pheochromocytoma and paraganglioma in relation to established risk factors of tumour size, location and *SDHB* mutation status. *Eur J Cancer*. 2012;48:1739–49. [DOI] [PubMed] [PMC]
44. Eisenhofer G, Lenders JWM, Timmers H, Mannelli M, Grebe SK, Hofbauer LC, et al. Measurements of plasma methoxytyramine, normetanephrine, and metanephrine as discriminators of different hereditary forms of pheochromocytoma. *Clin Chem*. 2011;57:411–20. [DOI] [PubMed] [PMC]
45. Eisenhofer G, Huynh T, Elkahloun A, Morris JC, Bratslavsky G, Linehan WM, et al. Differential expression of the regulated catecholamine secretory pathway in different hereditary forms of pheochromocytoma. *Am J Physiol Endocrinol Metab*. 2008;295:E1223–33. [DOI] [PubMed] [PMC]
46. Timmers HJLM, Pacak K, Huynh TT, Abu-Asab M, Tsokos M, Merino MJ, et al. Biochemically Silent Abdominal Paragangliomas in Patients with Mutations in the *Succinate Dehydrogenase Subunit B* gene. *J Clin Endocrinol Metab*. 2008;93:4826–32. [DOI] [PubMed] [PMC]
47. Timmers HJLM, Taïeb D, Pacak K, Lenders JWM. Imaging of Pheochromocytomas and Paragangliomas. *Endocr Rev*. 2024;45:414–34. [DOI] [PubMed] [PMC]
48. Carrasquillo JA, Chen CC, Jha A, Ling A, Lin FI, Pryma DA, et al. Imaging of Pheochromocytoma and Paraganglioma. *J Nucl Med*. 2021;62:1033–42. [DOI] [PubMed] [PMC]
49. Taïeb D, Hicks RJ, Hindié E, Guillet BA, Avram A, Ghedini P, et al. European Association of Nuclear Medicine Practice Guideline/Society of Nuclear Medicine and Molecular Imaging Procedure Standard 2019 for radionuclide imaging of phaeochromocytoma and paraganglioma. *Eur J Nucl Med Mol Imaging*. 2019;46:2112–37. [DOI] [PubMed] [PMC]
50. Taïeb D, Jha A, Treglia G, Pacak K. Molecular imaging and radionuclide therapy of pheochromocytoma and paraganglioma in the era of genomic characterization of disease subgroups. *Endocr Relat Cancer*. 2019;26:R627–52. [DOI] [PubMed] [PMC]
51. Fargette C, Shulkin B, Jha A, Pacak K, Taïeb D. Clinical utility of nuclear imaging in the evaluation of pediatric adrenal neoplasms. *Front Oncol*. 2023;12:1081783. [DOI] [PubMed] [PMC]
52. Carrasquillo JA, Chen CC, Jha A, Pacak K, Pryma DA, Lin FI. Systemic Radiopharmaceutical Therapy of Pheochromocytoma and Paraganglioma. *J Nucl Med*. 2021;62:1192–9. [DOI] [PubMed] [PMC]

53. Janssen I, Blanchet EM, Adams K, Chen CC, Millo CM, Herscovitch P, et al. Superiority of [⁶⁸Ga]-DOTATATE PET/CT to Other Functional Imaging Modalities in the Localization of *SDHB*-Associated Metastatic Pheochromocytoma and Paraganglioma. *Clin Cancer Res*. 2015;21:3888–95. [DOI] [PubMed] [PMC]
54. Jha A, Ling A, Millo C, Gupta G, Viana B, Lin FI, et al. Superiority of ⁶⁸Ga-DOTATATE over ¹⁸F-FDG and anatomic imaging in the detection of succinate dehydrogenase mutation (*SDHx*)-related pheochromocytoma and paraganglioma in the pediatric population. *Eur J Nucl Med Mol Imaging*. 2018;45:787–97. [DOI] [PubMed] [PMC]
55. Patel M, Jha A, Ling A, Chen CC, Millo C, Kuo MJM, et al. Performances of Functional and Anatomic Imaging Modalities in *Succinate Dehydrogenase A*-Related Metastatic Pheochromocytoma and Paraganglioma. *Cancers (Basel)*. 2022;14:3886. [DOI] [PubMed] [PMC]
56. Janssen I, Chen CC, Millo CM, Ling A, Taieb D, Lin FI, et al. PET/CT comparing ⁶⁸Ga-DOTATATE and other radiopharmaceuticals and in comparison with CT/MRI for the localization of sporadic metastatic pheochromocytoma and paraganglioma. *Eur J Nucl Med Mol Imaging*. 2016;43:1784–91. [DOI] [PubMed] [PMC]
57. Janssen I, Chen CC, Taieb D, Patronas NJ, Millo CM, Adams KT, et al. ⁶⁸Ga-DOTATATE PET/CT in the Localization of Head and Neck Paragangliomas Compared with Other Functional Imaging Modalities and CT/MRI. *J Nucl Med*. 2016;57:186–91. [DOI] [PubMed] [PMC]
58. Jha A, Patel M, Carrasquillo JA, Chen CC, Millo C, Maass-Moreno R, et al. Choice Is Good at Times: The Emergence of [⁶⁴Cu]Cu-DOTATATE-Based Somatostatin Receptor Imaging in the Era of [⁶⁸Ga]Ga-DOTATATE. *J Nucl Med*. 2022;63:1300–1. [DOI] [PubMed] [PMC]
59. Imperiale A, Pepponi M, Poterszman N, Jha A, Collen C, Brumaru D, et al. Molecular imaging phenotyping of germline fumarate hydratase (FH) pathogenic variant-positive metastatic pheochromocytoma. *Eur J Nucl Med Mol Imaging*. 2023;50:3155–6. [DOI] [PubMed]
60. Jha A, Ling A, Millo C, Chen C, Gupta G, Viana B, et al. Superiority of ⁶⁸Ga-DOTATATE PET/CT to other functional and anatomic imaging modalities in the detection of *SDHD*-related pheochromocytoma and paraganglioma—A comparative prospective study. *J Nucl Med*. 2018;59:46.
61. Janssen I, Chen CC, Zhuang Z, Millo CM, Wolf KI, Ling A, et al. Functional Imaging Signature of Patients Presenting with Polycythemia/Paraganglioma Syndromes. *J Nucl Med*. 2017;58:1236–42. [DOI] [PubMed] [PMC]
62. Pang Y, Gupta G, Jha A, Yue X, Wang H, Huynh TT, et al. Nonmosaic somatic *HIF2A* mutations associated with late onset polycythemia-paraganglioma syndrome: Newly recognized subclass of polycythemia-paraganglioma syndrome. *Cancer*. 2019;125:1258–66. [DOI] [PubMed] [PMC]
63. Taieb D, Jha A, Guerin C, Pang Y, Adams KT, Chen CC, et al. ¹⁸F-FDOPA PET/CT Imaging of *MAX*-Related Pheochromocytoma. *J Clin Endocrinol Metab*. 2018;103:1574–82. [DOI] [PubMed] [PMC]
64. Jha A, Patel M, Ling A, Chen C, Millo C, Charles K, et al. Diagnostic performance of PET or PET/CT utilizing ¹⁸F-FDOPA, ⁶⁸Ga-DOTATATE, ¹⁸F-FDG, ¹⁸F-FDA, and CT and MRI in the detection of *MEN2A*-related pheochromocytoma—A comparative prospective study. *J Nucl Med*. 2022;63:3014.
65. Tepede AA, Welch J, Lee M, Mandl A, Agarwal SK, Nilubol N, et al. ¹⁸F-FDOPA PET/CT accurately identifies *MEN1*-associated pheochromocytoma. *Endocrinol Diabetes Metab Case Rep*. 2020;2020:19-0156. [DOI] [PubMed] [PMC]
66. Nambuba J, Därr R, Janssen I, Bullova P, Adams KT, Millo C, et al. Functional Imaging Experience in a Germline Fumarate Hydratase Mutation—Positive Patient With Pheochromocytoma and Paraganglioma. *AACE Clin Case Rep*. 2016;2:e176–81. [DOI]
67. Jha A, Patel M, Carrasquillo JA, Ling A, Millo C, Saboury B, et al. Sporadic Primary Pheochromocytoma: A Prospective Intraindividual Comparison of Six Imaging Tests (CT, MRI, and PET/CT Using ⁶⁸Ga-DOTATATE, FDG, ¹⁸F-FDOPA, and ¹⁸F-FDA). *AJR Am J Roentgenol*. 2022;218:342–50. [DOI] [PubMed] [PMC]

68. Jha A, Taieb D, Carrasquillo JA, Pryma DA, Patel M, Millo C, et al. High-Specific-Activity-¹³¹I-MIBG versus ¹⁷⁷Lu-DOTATATE Targeted Radionuclide Therapy for Metastatic Pheochromocytoma and Paraganglioma. *Clin Cancer Res*. 2021;27:2989–95. [DOI] [PubMed] [PMC]
69. Nölting S, Bechmann N, Taieb D, Beuschlein F, Fassnacht M, Kroiss M, et al. Personalized Management of Pheochromocytoma and Paraganglioma. *Endocr Rev*. 2022;43:199–239. [DOI] [PubMed] [PMC]
70. Wang K, Crona J, Beuschlein F, Grossman AB, Pacak K, Nölting S. Targeted Therapies in Pheochromocytoma and Paraganglioma. *J Clin Endocrinol Metab*. 2022;107:2963–72. [DOI] [PubMed] [PMC]
71. Jimenez C, Subbiah V, Stephen B, Ma J, Milton D, Xu M, et al. Phase II Clinical Trial of Pembrolizumab in Patients with Progressive Metastatic Pheochromocytomas and Paragangliomas. *Cancers (Basel)*. 2020;12:2307. [DOI] [PubMed] [PMC]
72. Angelousi A, Tzoulis P, Tsoi M, Chatzellis E, Koumariannou A, Kaltsas G. Immunotherapy for endocrine tumours: a clinician's perspective. *Endocr Relat Cancer*. 2024;31:e230296. [DOI] [PubMed]
73. Jimenez C, Armaiz-Pena G, Dahia PLM, Lu Y, Toledo RA, Varghese J, et al. Endocrine and Neuroendocrine Tumors Special Issue-Checkpoint Inhibitors for Adrenocortical Carcinoma and Metastatic Pheochromocytoma and Paraganglioma: Do They Work? *Cancers (Basel)*. 2022;14:467. [DOI] [PubMed] [PMC]
74. Ramirez RA, Beyer DT, Chauhan A, Boudreaux JP, Wang Y, Woltering EA. The Role of Capecitabine/Temozolomide in Metastatic Neuroendocrine Tumors. *Oncologist*. 2016;21:671–5. [DOI] [PubMed] [PMC]
75. Baudin E, Goichot B, Berruti A, Hadoux J, Moalla S, Laboureaux S, et al. ENDOCAN-COMETE, ENSAT Networks. Sunitinib for metastatic progressive phaeochromocytomas and paragangliomas: results from FIRSTMAPPP, an academic, multicentre, international, randomised, placebo-controlled, double-blind, phase 2 trial. *Lancet*. 2024;403:1061–70. [DOI] [PubMed]
76. Tian R, Yao X, Song J, Wang J, Fu J, Shi L, et al. Anlotinib for Metastatic Progressed Pheochromocytoma and Paraganglioma: A Retrospective Study of Real-World Data. *J Endocr Soc*. 2024;8:bvae061. [DOI] [PubMed] [PMC]
77. Al-Ward R, Brondani VB, Sawani S, Potter CL, Xu G, Waguespack SG, et al. High-Specific-Activity ¹³¹I-MIBG for the Treatment of Advanced Pheochromocytoma and Paraganglioma. *Clin Nucl Med*. 2024;49:610–20. [DOI] [PubMed]
78. Gubbi S, Al-Jundi M, Auh S, Jha A, Zou J, Shamis I, et al. Early short-term effects on catecholamine levels and pituitary function in patients with pheochromocytoma or paraganglioma treated with [¹⁷⁷Lu]Lu-DOTA-TATE therapy. *Front Endocrinol (Lausanne)*. 2023;14:1275813. [DOI] [PubMed] [PMC]
79. Gubbi S, Al-Jundi M, Del Rivero J, Jha A, Knue M, Zou J, et al. Case Report: Primary Hypothyroidism Associated with Lutetium 177-DOTATATE Therapy for Metastatic Paraganglioma. *Front Endocrinol (Lausanne)*. 2021;11:587065. [DOI] [PubMed] [PMC]
80. Patel M, Tena I, Jha A, Taieb D, Pacak K. Somatostatin Receptors and Analogs in Pheochromocytoma and Paraganglioma: Old Players in a New Precision Medicine World. *Front Endocrinol (Lausanne)*. 2021;12:625312. [DOI] [PubMed] [PMC]
81. Jha A, Patel M, Baker E, Gonzales MK, Ling A, Millo C, et al. Role of ⁶⁸Ga-DOTATATE PET/CT in a Case of *SDHB*-Related Pterygopalatine Fossa Paraganglioma Successfully Controlled with Octreotide. *Nucl Med Mol Imaging*. 2020;54:48–52. [DOI] [PubMed] [PMC]
82. Jha A, Nilubol N, Pacak K. Some Considerations in Treating Malignant Head and Neck Paragangliomas. *JAMA Otolaryngol Head Neck Surg*. 2020;146:209–10. [DOI] [PubMed] [PMC]
83. Lastoria S, Maurea S, Vergara E, Acampa W, Varrella P, Klain M, et al. Comparison of labeled MIBG and somatostatin analogs in imaging neuroendocrine tumors. *Q J Nucl Med*. 1995;39:145–9. [PubMed]
84. Maurea S, Lastoria S, Caracò C, Klain M, Varrella P, Acampa W, et al. The role of radiolabeled somatostatin analogs in adrenal imaging. *Nucl Med Biol*. 1996;23:677–80. [DOI] [PubMed]

85. Lin FI, Del Rivero J, Carrasquillo J, Shamis I, Zou J, Turkbey B, et al. Phase 2 trial of lu-177-DOTATATE in metastatic or inoperable pheochromocytoma/paraganglioma: interim analysis results. *J Nucl Med*. 2023;64:1296. [DOI]
86. Kamihara J, Hamilton KV, Pollard JA, Clinton CM, Madden JA, Lin J, et al. Belzutifan, a Potent HIF2 α Inhibitor, in the Pacak-Zhuang Syndrome. *N Engl J Med*. 2021;385:2059–65. [DOI] [PubMed] [PMC]
87. Curry L, Soleimani M. Belzutifan: a novel therapeutic for the management of von Hippel-Lindau disease and beyond. *Future Oncol*. 2024;20:1251–66. [DOI] [PubMed]
88. Else T, Jonasch E, Iliopoulos O, Beckermann KE, Narayan V, Maughan BL, et al. Belzutifan for von Hippel-Lindau Disease: Pancreatic Lesion Population of the Phase 2 LITESPARK-004 Study. *Clin Cancer Res*. 2024;30:1750–7. [DOI] [PubMed] [PMC]
89. Yadav MP, Ballal S, Sahoo RK, Bal C. Efficacy and safety of ²²⁵Ac-DOTATATE targeted alpha therapy in metastatic paragangliomas: a pilot study. *Eur J Nucl Med Mol Imaging*. 2022;49:1595–606. [DOI] [PubMed] [PMC]
90. Toledo RA, Jimenez C, Armaiz-Pena G, Arenillas C, Capdevila J, Dahia PLM. Hypoxia-Inducible Factor 2 Alpha (HIF2 α) Inhibitors: Targeting Genetically Driven Tumor Hypoxia. *Endocr Rev*. 2023;44:312–22. [DOI] [PubMed] [PMC]
91. Harrison L, Blackwell K. Hypoxia and anemia: factors in decreased sensitivity to radiation therapy and chemotherapy? *Oncologist*. 2004;9:31–40. [DOI] [PubMed]